


## COMBINED DISSECTION AND COAGULATION OF A MASTOID TUMOR USING A HAND-HELD CO<sub>2</sub> LASER FIBER

**Elias M. Michaelides, MD**  
*Assistant Professor and Director  
Yale Hearing & Balance Program  
New Haven, CT*



The patient, a 2 year-old male, had no history of ear disease. Drainage, which did not respond to standard antibiotics, was noted from his right ear for several months. Upon inspection, a mass was found in his right ear canal, identified by biopsy as Langerhans cell histiocytosis. CT and MRI scans showed a mass in the mastoid, eroding into the ear canal and through the tegmen towards the middle cranial fossa and temporal lobe. The patient was taken to the operating room for surgical debulking of the tumor. Once the tumor was identified, it was noted to be quite vascular and oozed with manipulation. The CO<sub>2</sub> laser fiber (BeamPath™ OTO-S) was introduced for bloodless dissection. Inert gas flow cleared the surgical field of blood and debris and assisted with coagulation. The CO<sub>2</sub> laser fiber allowed for combined cutting and coagulation for efficient debulking of the vascular tumor. Postoperatively, the patient did very well with no subsequent hemorrhage. The patient was started on a course of chemotherapy to complete treatment.

## PATIENT PROFILE

2 year-old male with no previous history of ear disease.

Drainage from the right ear was noted for several months, did not respond to standard treatment with antibiotics.

A mass was found in the ear canal and a biopsy identified it as Langerhans cell histiocytosis.

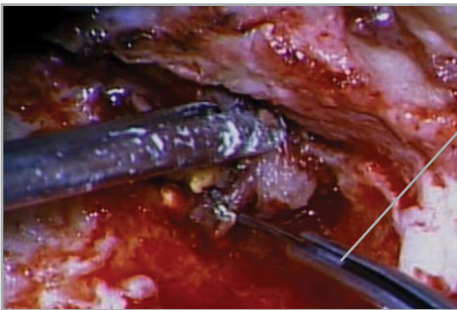
CT and MRI scans showed a mass in the mastoid eroding into the ear canal and through the tegmen towards the middle cranial fossa and temporal lobe.

## SURGICAL COURSE

- Under anesthesia a postauricular approach was used due to the position of the tumor, extending from the mastoid into the ear canal.
- Once the tumor was identified, it was noted to be quite vascular and oozed with manipulation.
- The CO<sub>2</sub> laser fiber (BeamPath™ OTO-S) was then introduced for combined cutting and coagulation of the vascular tumor tissue (*Fig. 1&2*).
- The fiber was used with a 250 μm spot size diameter at a power setting of 4 watts with 0.1 sec short pulses. The laser was used in continuous wave for hemostasis and superpulse for cutting.
- Vascular portions of the tumor were coagulated using the fiber slightly retracted from the target tissue in order to disperse the laser energy.
- The tumor was removed easily in several segments with good hemostasis (*Fig. 3&4*).
- A layer of tumor was left on the facial nerve and the dura of the middle fossa to avoid risk of injury to these structures.

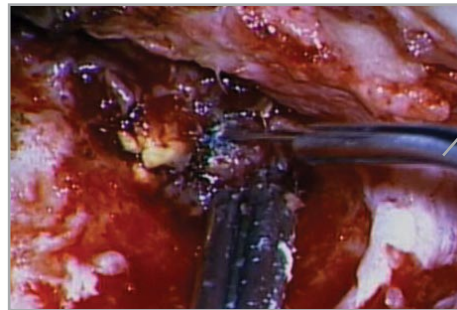
## POSTOPERATIVE RESULTS

Postoperatively, the patient did very well with no subsequent hemorrhage. The patient was started on a course of chemotherapy.



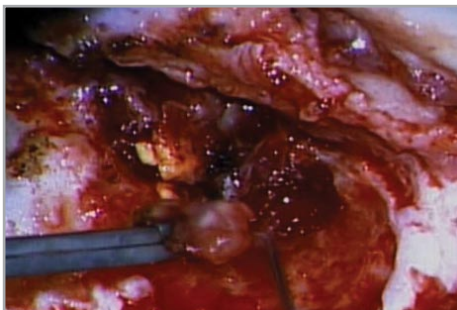
BeamPath™  
OTO-S Fiber

*Figure 1: Fine dissection using the BeamPath™ OTO-S Fiber*

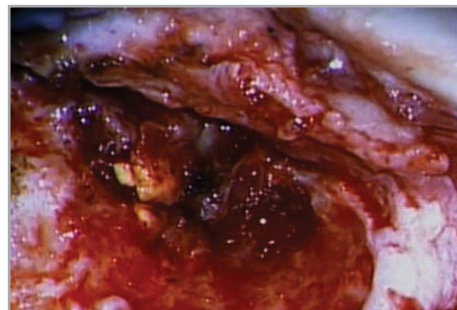


BeamPath™  
OTO-S Fiber

*Figure 2: Coagulation using the BeamPath™ OTO-S Fiber*



*Figure 3: Tumor section removed*



*Figure 4: Tumor debulked following removal of vascular sections*

## DISCUSSION

The CO<sub>2</sub> laser fiber served as both a cutting and coagulation tool. Since the vascular tumor oozed considerably when handled with standard surgical tools, the CO<sub>2</sub> laser fiber was needed for efficient, hemostatic debulking of the tumor. The inert gas flow through the fiber cleared the surgical field of blood and debris, enhancing the fiber's cutting and coagulation abilities. The flow ensured that the laser energy was not absorbed by pooling blood, and

oozing capillaries were more readily coagulated. The absorption characteristics of CO<sub>2</sub> laser energy in tissue and consequently the minimal thermal spread associated with it allowed for safe dissection close to delicate anatomy such as the facial nerve and dura mater. The BeamPath™ OTO-S CO<sub>2</sub> laser fiber (OmniGuide®, Cambridge, MA) enabled precise removal of tumor tissue section by section in a safe and efficient manner.

